



TRAINING INSTITUTE on STRANGULATION PREVENTION

JUNE/JULY 2020 E-NEWS: IMAGING TOOLKIT

Dear Friends,

Thank you for joining our recently held webinar on Imaging Recommendations for the Patient who is Strangled. Due to the overwhelming interest in our sold-out Imaging webinar, our E-news on Imaging, and the questions that have poured in, we decided to create this Imaging Toolkit to share with you for our June/July E-News.

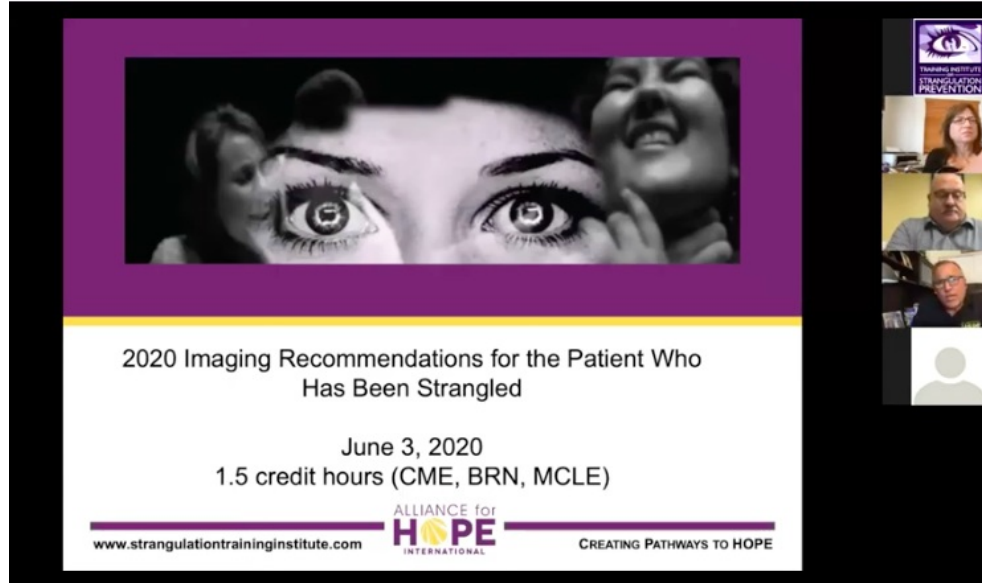
The Training Institute on Strangulation Prevention thanks you for your passion and commitment to promoting victim safety, health and well-being. We are continuously inspired by your determination to **DO MORE** for the patient who has been strangled and how to best implement promising practices in your community. For this E-News, we have included resources and a recording of our webinar so you can watch, share, and continue saving lives!

Always with great HOPE,

Gael, Casey, Karly, and Emma



NEW! 2020 IMAGING WEBINAR



[CLICK HERE](#) to watch our webinar "2020 Imaging Recommendations for the Patient who has been Strangled: Saving the Lives of Survivors"

The Training Institute on Strangulation Prevention is excited to host our second webinar on Imaging Recommendations for the Patient who has been Strangled with leading forensic experts in the field. Together, the panelists cover:

- The long journey to Imaging
- How & why the recommendations were developed
- The top 5 FAQs about implementing the imaging recommendations
- Updates and lessons learned since the recommendations that were first published in 2016
- Review of recent imaging articles
- Recommendations for the patient who has been strangled
- Questions from attendees

Quotes from Panelists:

"Imaging provides peace of mind to patients and professionals. I would rather have an early diagnosis than a missed diagnosis. I would rather have a negative finding than a positive finding. A negative finding is priceless. A misdiagnosis is catastrophic." - Gael Strack, J.D.

"Most victims of strangulation and/or suffocation have internal injuries. An external examination is not enough. The only way to diagnose an internal injury is imaging or an autopsy. Victims of strangulation deserve the right to imaging similar to any other injured patient." - Casey Gwinn, J.D.

"New data involving the complex and controversial question of diagnostic imaging of the strangled patient is finally bringing consensus and clarity to the issue." - Dr. William Green

"Strangulation...more common and potentially more lethal than you think; get the facts and guidance you need to know to make a difference." - Dr. Ralph Riviello

"Given the current state of our medical knowledge and the morbidity and mortality associated with a missed arterial injury in the neck, it is malpractice to *not* order a

screening CTA in the non-fatal strangled patient.” - Dr. William Smock

"This webinar will review and critique recently published research on imaging for patients that have been strangled, and discuss unique emergency department considerations for those providing that care." - Dr. Michael Weaver

FAQs FROM THE IMAGING WEBINAR

PEDIATRIC

FAQ



MEDICAL

FAQ



IMPLEMENTATION

FAQ



ADVOCACY

FAQ



CLICK HERE TO READ OUR LATEST ARTICLE:

WHY IMAGING IS SO IMPORTANT



[illegible]

REFERENCES

*Indicates a paper based upon a review of case studies, and/or clinical and laboratory literature

1. Christie A, Wright J, Ross S, et al. Life-threatening virus-associated thrombocytopenic purpura: are there appropriate criteria for MRI imaging of the spine? *Eur Radiol* 2000;10: 1882-1889.
2. Azzouz A, Oussoult D, Houton R, et al. Spinal cord involvement in Dengue virus infection: a case report and review of the literature. *Emerg Infect Dis* 2006;12:1282-1283.
3. Yen K-H, Mok M, Aghayee E, et al. Strangulation Signs: Initial Correlation of MRI, PET-CT, and Forensic Necropsy Findings in a Fatal Case. *Am J Forensic Med Pathol* 2009;23:120-124.
4. Szekely ZS. Strangulation injuries. *Emergency Medicine Topics* 2013;17(1):193-203.
5. Yen K, Mok A, Chan A, et al. Clinical Forensic Radiology in Strangulation Victims: Forensic expertise based on forensic radiologic imaging (MRI) findings. *Am J Forensic Med Pathol* 2007;21:111-115.
6. Vaidhyanathan M, Hishigata RT, Haback VL, et al. Patient Presentation Anatomic Features and Treatment of Strangulation-Related Cervical Brachial Plexus Lesions of the Cervical Cord Artery. *Report of three cases, J Neurosurg* 2000;93:681-687.
7. Di Paolo M, Gudi B, Bruschini L, et al. Unexpected delayed death after manual strangulation: need for forensic investigation in the emergency room. *Am J Surg* 2004;187:723-724.
8. Dayalappa A, Samarakone A and Jayaram A. An Uncommon Delayed After Sequela After Pressure on the Neck: A Diagnostic Case Report. *Am J Forensic Med Pathol* 2013;23:48-52.
9. Hesse M, Kuchta M, et al. Delayed Post-Strangulation Encephalopathy After Sequela. *Arch Neurol* 1994;51:1491-1494.
10. Jacobson E, Nayer M, Fleming J, Low-Gor S. A pain in the neck: a rare case of isolated hyaloid body hemorrhage. *JHCJ* 2011;17(3).
11. Oh J, Min HS, Park ST, Park SH, Kim SE. Delayed Isolated Cerebral Fractures Associated with Blunt Neck Trauma. *Am J Forensic Med Pathol* 2013;23:45-47.
12. Githinji PK, Cavill PJ, Giff S, Galt-Harris Z. Homoidal Neck Compression of Females: Autopsy and Sexual Assault Findings. *Am J Forensic Med Pathol* 2013;23:45-47.
13. Githinji PK, Muthu J, Tegenfeldt J, Anwar E. Delayed Lateral and Medial Cerebral Artery Hemorrhagic Infarctions After Altered Strangulation. A case report. *Am J Forensic Med Pathol* 2013;23:105-106.
14. Ziaei F, Baei F, Poudi B, Frouzi B. Delayed Lateral Brachial Plexus Delayed Cervical Artery Dissection after Manual Strangulation. *Forensic Sci Int* 2006;162:100-102.
15. Molokaj J, Waxa J, Fendek T, Fendek T. Bilateral Post-Traumatic Cerebral Artery Dissection as a Result of Strangulation Injury. *Am J Forensic Med Pathol* 2013;23:48-52.
16. Plattner T, Bollinger S, Zallinger U. Forensic Assessment of Survived Strangulation. *Forensic Sci Int* 2005;150:207-209.
17. Wang S, Li C, Wang M, et al. Delusional Paraphrenia with Selective Symptomatology. *Am J Geriatr Psychiatry* 2009;17:973-975.
18. Purani V. Unilateral Headache and Paresthesia in a 30-year-Old Woman. *Sunn Ophthalmol* 1997;4(2):115-118.
19. Hays RD, Hays RD, Marshall CR, et al. Cervical Artery Dissection in Cervical Artery Dissection: A case report and review of the current literature. *Ann Vasc Surg* 2014;28:738-739-40.
20. Chakravarty T, myamamoto T, Yamada H, Tanaka T, Sakurai T. Transcatheter Brachial Artery Cervical Artery Dissection. *Am J Forensic Med Pathol* 2013;23:48-52.
21. Chakravarty T, myamamoto T, Yamada H, Tanaka T, Sakurai T. Transcatheter Brachial Artery Cervical Artery Dissection. *Am J Forensic Med Pathol* 2013;23:48-52.

This report is prepared as part of a peer review for the 2018-2019 Academic year by the Office on Violence Against Women, US Department of Justice. The opinions, findings, conclusions, and recommendations expressed in this publication are those of the author(s) and do not necessarily reflect those of the Department of Justice, Office on Violence Against Women.

[illegible]

Facts Victims of Strangulation(Choking) Need to Know

4-Minute Imaging Video with Dr. Smock
2-Minute PSA Video from the Institute
NY Medical Alert on Imaging
San Diego Medical Alert on Imaging
Letter to the Editor - Response to the KY Article on CTAs
Dear Doctor Letter



CLICK HERE TO JOIN OUR LIST OF
**ADOPTING MEDICAL
PROVIDERS**

JOIN US ON FACEBOOK LIVE

A background image for a Facebook Live event. It shows a person's hands holding a glowing, sun-like orb. The person's face is partially visible on the left, looking towards the orb. The background is a soft, hazy landscape.

Join us for a
SNEAK PEEK
from the Institute
WEDNESDAYS @ 8:00 AM PST

A square logo with a stylized eye graphic. Below the eye, the text reads "TRAINING INSTITUTE on STRANGULATION PREVENTION".The Facebook Live logo, consisting of a blue square with a white 'f' and a red rectangle with the word "LIVE" in white.

This project is supported all or in part by Grant No. 2016-TA-AX-K067 awarded by the Office on Violence Against Women, U.S. Department of Justice. The opinions, findings, conclusions, and recommendations expressed in this publication/program/exhibition are those of the author(s) and do not necessarily reflect the views of the Department of Justice, Office on Violence Against Women.

The Training Institute on Strangulation Prevention

Alliance for HOPE International

Toll Free: (888) 511-3522

Local: (619) 236-9551

www.allianceforhope.com

www.strangulationtraininginstitute.com

